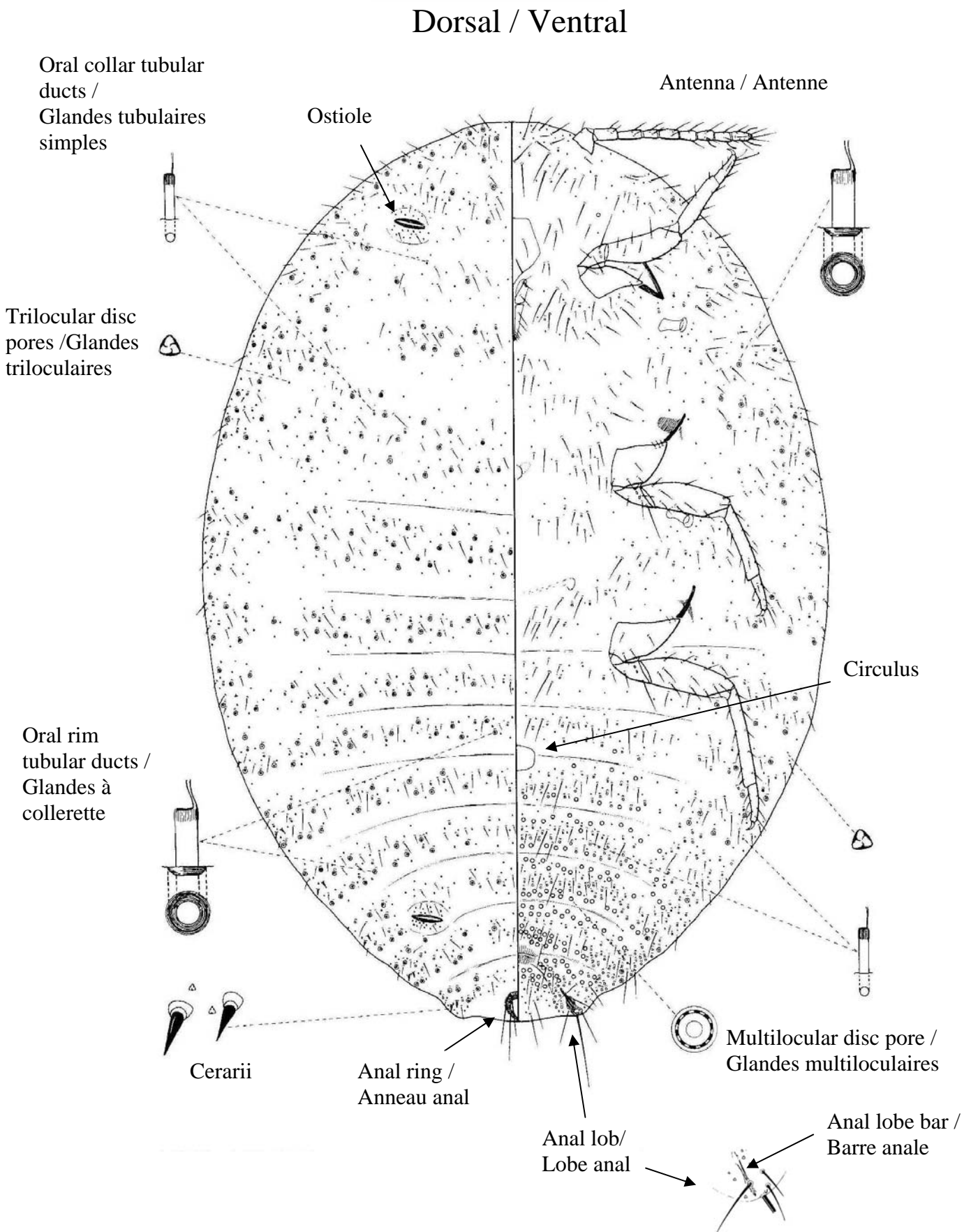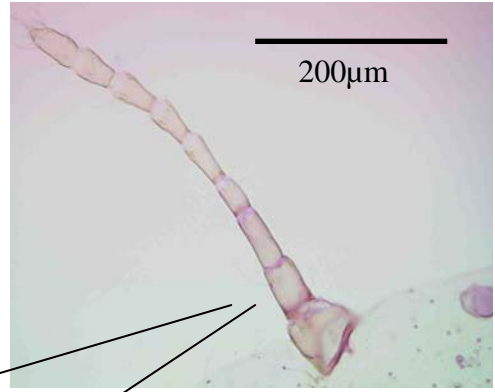
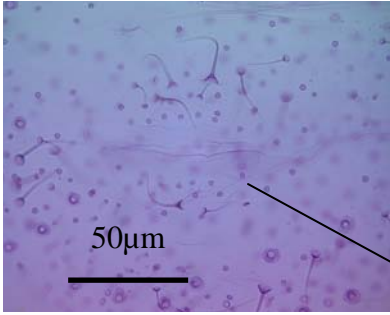


**Web Fig. 1: Morphological description *Maconellicoccus hirsutus***  
 (after Williams & Watson, 1988)

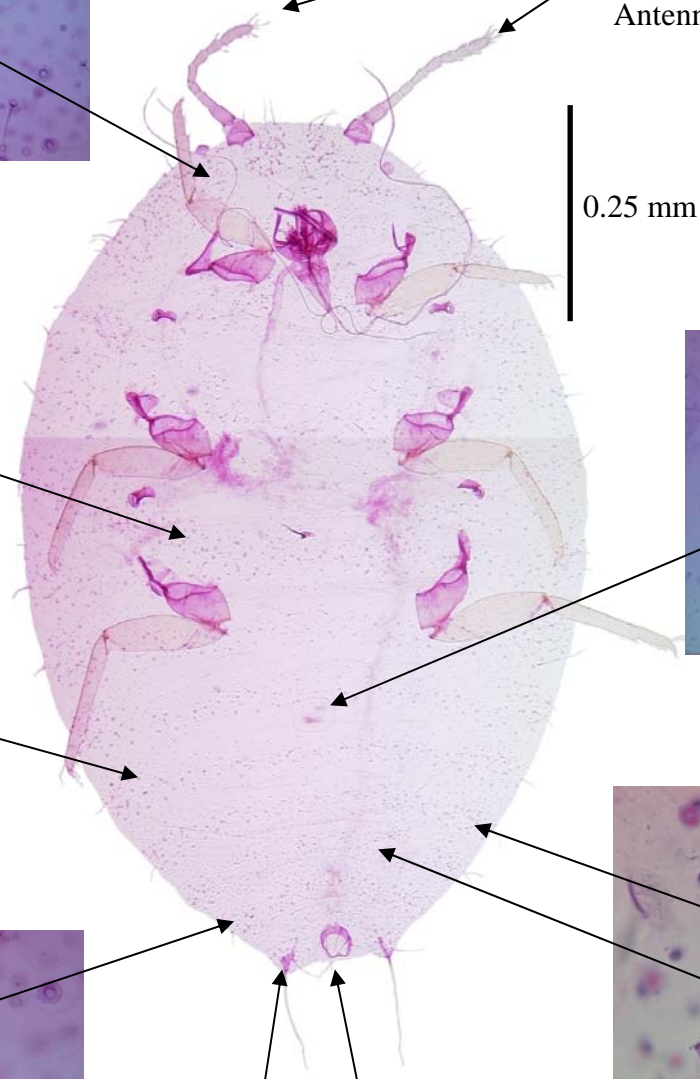
(D) : dorsal  
(V) : ventral



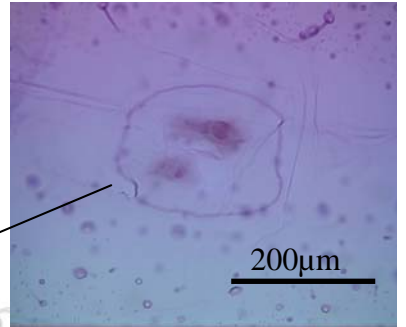
Antenna / Antenne (V)



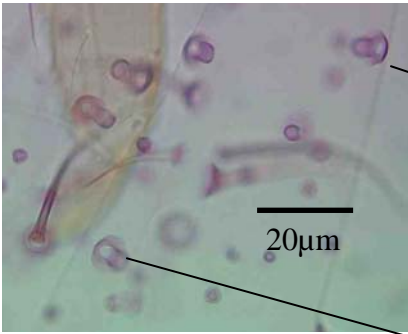
Ostiole (D)



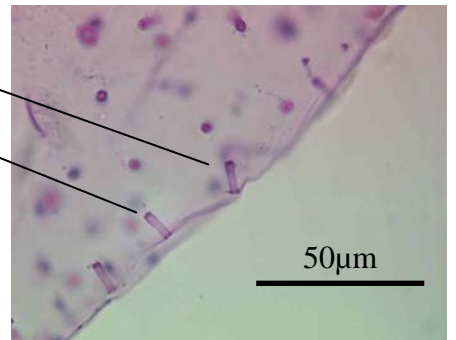
0.25 mm



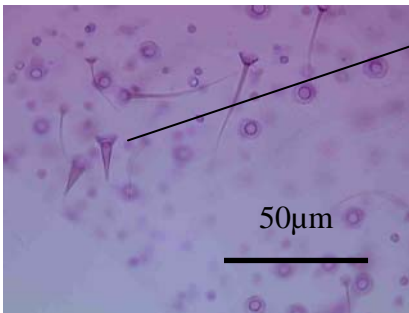
Circulus (V)



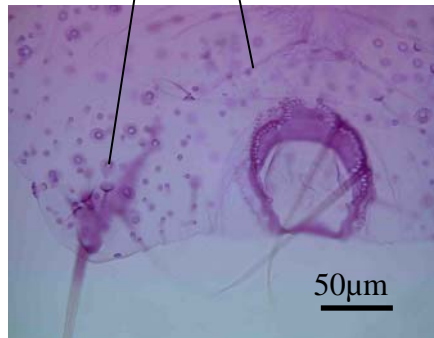
Oral rim tubular ducts  
Glandes à collerette (D/V)



Oral collar tubular ducts /  
Glandes tubulaires simples (D/V)



Cerarii (D)



Anal ring / Anneau  
anal (D)

Anal lobe bar /  
Barre anale (V)

**Web Fig. 2 : *Maconellicoccus hirsutus*, slide mounted observations**